

Surgical removal of a dislocated lower third molar from the condyle region: Case report

A. Wassouf*, G. Eyrich, R. Lebeda, K. W. Grätz

* Department of Cranio-Maxillofacial Surgery at University Hospital of Zurich – Switzerland

Key words: aberrated lower third molar, condylar region

Corresponding author:

Anas Wassouf

Rämistrasse 100

8091 Zurich, Switzerland

Phone: 0041-1-2551111

E-Mail: wassoufaa@yahoo.com

Introduction: Removal of dislocated lower third molar into the condylar region is quite rare. Attention should be taken to avoid condyle fracture.

Methods: 49-year-old patient had an ectopic lower left third molar in the condylar region, suffered from a submandibular and masseter space abscess. Removal of the molar via intraoral approach was chosen avoiding facial nerve branches and unnecessary scar formation. Coronoid process is removed, the tooth is separated and removed. The defect is filled with iliac cancellous bone. The coronoid process was fixed as a cover with a resorbable plate and screws (BIONX®).

Results: Removal via intraoral approach is possible. Hypesthesia existed postoperatively, became normal later.

Conclusion: annual observation is strongly recommended. Intraoral approach is superior to the extraoral approach. Removal of the coronoid process minimize the masticator forces. Separation of the tooth is essential. Filling the defect with cancellous bone accelerates the healing.

Summary

Aberration of the lower third molar to the ascending ramus is a rare situation in wisdom tooth removal. Furthermore, displacement of the third molar into the condyle is a unique scenario. Those conditions may be severed by an adjacent cyst. A 49-year-old white female with a condylar aberration of the lower wisdom tooth with follicular cystic formation is presented. The surgical approach, its pros and cons, as well as the defect reconstruction are demonstrated and discussed.

The surgical approach and exposing the tooth from the buccal aspect of the ascending ramus after removing the coronoid process

Introduction

Surgical removal of migrated wisdom teeth may be demanding. The type of surgical approach has to take the following considerations into account, such as close vicinity of vital anatomic structures, function, defect reconstruction, possible adverse scarring etc. In addition, considering possible damage, a clear indication must justify the risk of such an operation. The following case report demonstrates the decision making and process in such a rare situation.

Clinical Course

At the first clinical visit the patient presented a solid painful swelling in the massetrico-mandibular region. The region of the left mandibular angle was also tender to palpation. The otherwise healthy patient showed no lymphadenopathy or loss of nerve function. Mouth opening was limited to 5 mm. The medical history revealed no previous medical or dental interventions in the head and neck.

Panoramic radiographs (fig. 1) showed a wisdom tooth dislocated highly to the left condyle. In immediate vicinity to the downward rotated crown, a radiolucency was depicted. For precise imaging of the relationship of the tooth to anatomic structures and the adjacent radiolucency, CT-scans were obtained. CT-scans documented the central condylar position of the tooth and the cystic-like bony lesion with its proximity to the inferior alveolar nerve (fig. 2). The buccal cortex was partly incomplete and eroded by the tooth. Soft tissues showed a perimandibular/parapharyngeal abscess formation.

A submandibular incision and extraoral drainage under general anesthesia was performed. During the hospital course, 3×2.2 g Amoxicillin/Clavulanacid (Augmentin®) was daily intravenously administered. After significant improvement the patient was finally discharged on day seven. After a thorough DPRQ-conference with the patient, informed consent for the wisdom tooth removal was obtained. The operation was scheduled three months postoperative to the prior intervention.

Operative Description

After an endonasal tube was introduced successfully on the right side, monitors were applied. The patient was prepped and draped in a typical sterile fashion.

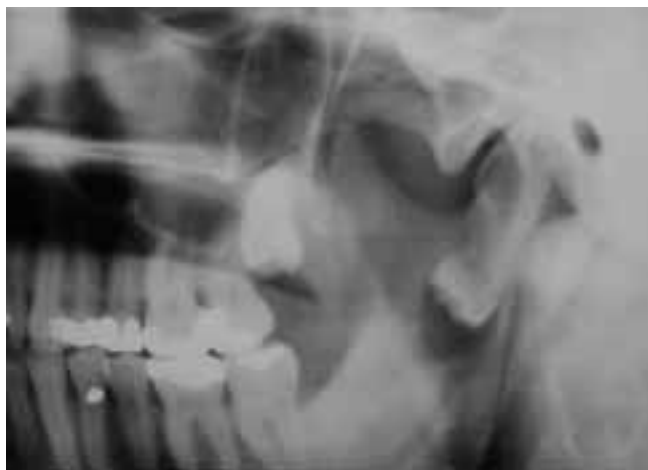

Fig. 1 Panoramic x-ray showing the high dislocation of the left lower third molar into the condylar region

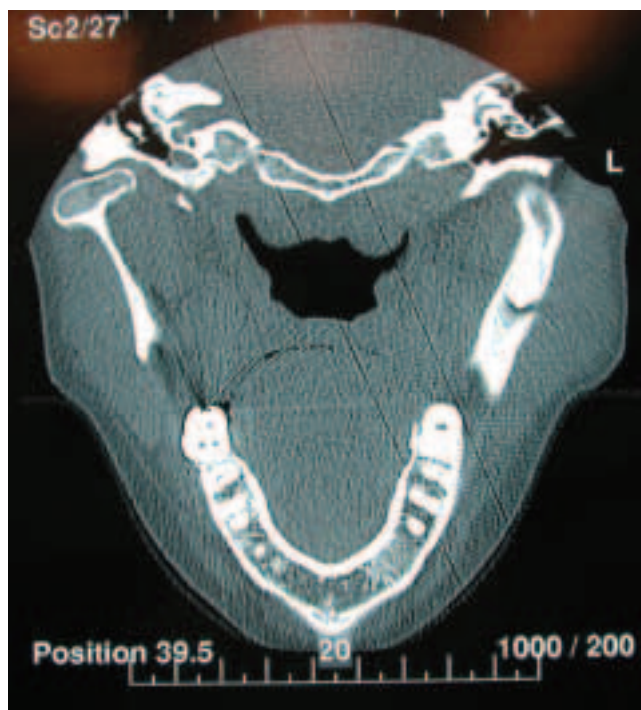


Fig. 2 CT-scan section showing the position of the tooth and the buccal perforation

An intraoral incision was performed from along the ramus approx. 15 mm above the occlusal plane downward to the external oblique ridge to the distal region of tooth number 35. The ramus was then dissected free buccally and lingually, so was the buccal aspect of the mandibular angle. An inner channel was placed on the lingual aspect of the ramus and a malleable on the buccal side. The coronoid process was freed from inserting tendons and cut in an oblique-horizontal direction downward. The coronoid process was preserved and stored in saline solution. The crown was located in a slightly convex area of the buccal compacta. The overlying bone was removed utilizing a 3 mm diameter round burr (fig. 3). In addition, the cystic cavity next to the crown was opened. This allowed sufficient access while sparing the bony frame at the anterior and posterior edges. With the fissure burr (Toller burr) on the straight surgical hand piece, the lower part of the crown was separated and the first piece of the crown was removed. Then using the contra angle surgical hand piece with the same fissure burr, another separation was performed to cut and remove the rest of the crown. The contra angle hand piece was chosen because of serious difficulties due to the narrow space when performing the second separation of the tooth. Using the fissure burr on the straight hand piece the two roots could be diminished and separated in different pieces to facilitate removal. After removing the roots, the remaining soft tissues were removed and sent to pathology. Care was taken to avoid any severing of the mandibular nerve on the lingual lower side of the defect.

After estimation of the bony defect, monocortical bone of a size of 25×25×7 mm was harvested from the iliac crest. The defect was filled with cancellous and cortical bone chips. The coronoid process was trimmed to fit as a cortical plate covering the buccal site and fixed with an absorbable 2 mm 4 hole plate and 8 mm screws (BIONX) (fig. 4). Wound closure was achieved by a 0/3 Supramid running suture. Elastic intermaxillary closure with rubber bands was applied to prevent excessive forces.

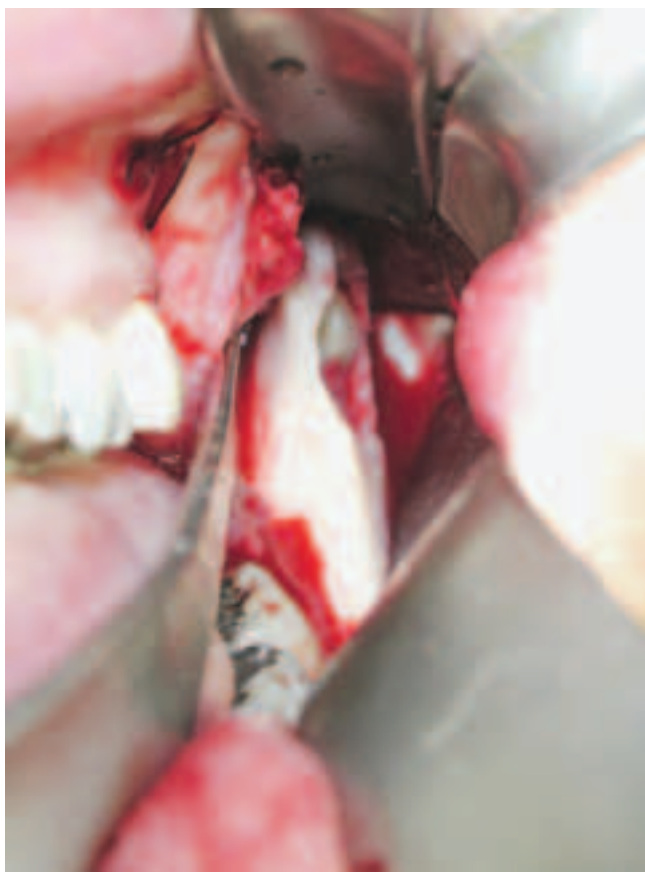

Fig. 3 The surgical approach and exposing the tooth from the buccal aspect of the ascending ramus after removing the coronoid process

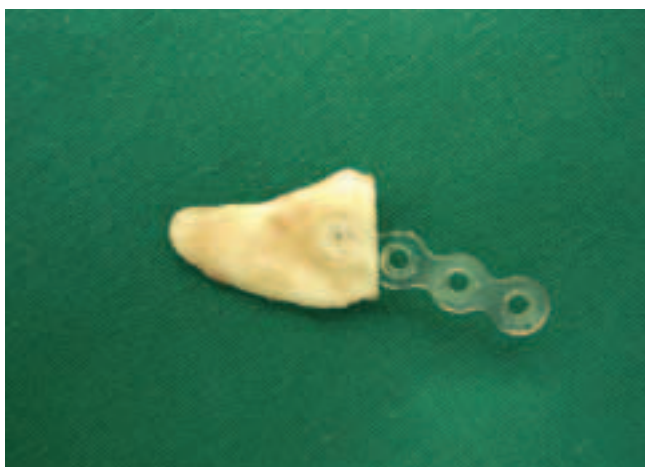

Fig. 4 The coronoid process and the resorbable plate 2.0 system BIONX

On the same day the patient was discharged from the recovery room and brought to the ward.

Pre- and postoperatively the patient was given antibiotics (Amoxicillin/Clavulanacid Augmentin 3×625 mg/for 10 days) and pain medication (Mephanamicacid 2×500 mg for several days), Chlorhexidine 0.2% mouth rinsing was applied for 14 days. In the postoperative examination the patient reported mild dysesthesia in the lower lip on the left side. Relief was recorded after day 7. Sutures were removed on day 10. The pathology report revealed a follicular cyst.

Discussion

Highly migrated impacted third molars in the condyle region are rare. Only a few cases are reported in the literature. NODINE (1946) reported 14 third molars in the neck of the condyle. BALENDRA (1949) and ZERNOV (1949) also described third molars in the condylar area. ZERLIP (1978) reported a case of a displaced third molar with a dentogenous cyst in the condylar area.

High resolution CT-scans of the ascending ramus are of high value in evaluating the anatomic relationship and planning the operative strategy. LOCHER & PAJAROLA (1995) stated in cases without urgent necessity, annual control to monitor growth of the follicular cyst is appropriate. BURTON (1980) described a case of infection with *Serratia* in a patient with two highly impacted third lower molars in the lower ramus and the condylar region. However, this case is considered to be of high risk with a justified indication for removal (infection of cyst and subsequent abscess formation).

Preventing fracture of the condylar neck and damage to neuronal structures are paramount. In addition, adverse scar formation in facial areas especially in younger patients should be avoided.

The operative strategy includes three possible approaches: the intraoral route, preauricular incision and submandibular incision along the ramus. The patients permission for all three routes enhances the freedom of the surgeon. However, the intraoral route gives sufficient access while avoiding extraoral scar formation, damage of joint components and risk to neuronal structures such as the facial nerve. The intraoral approach is, therefore, first on the list adding, the others are secondary options if necessary. Use of headlights, extra-long instruments and angulated handpieces are of great help when choosing the intraoral route.

The most critical situation is the removal of the tooth from the neck, because the remaining bone frequently is partly eroded leaving a weak and incomplete paper thin frame. Any force directed toward this frame causes instant fracture. Applying forces from within the structure (tooth) and towards parts of the structure is most preserving. OIKARINEN & ALTONEN (1970) described a comparable case. The removal was carried out in a more extensive fashion utilizing an extraoral approach and osteotomy and removal of the condyle with the impacted molar was achieved. However, this aggressive strategy puts joint structures, neuronal structures at risk and produces avoidable scar formation. In case of an unfortunate fracture any type of stabilization is extremely difficult due to the small amount of bone available for screw or wire placement. Therefore, it seems to be permissible to leave small dental pieces ($\times < 1$ mm) in place if a fracture would be the cause of complete removal.

Defects bigger in size than the removed tooth almost always require reconstruction. Osteotomy of the coronoid process reduces biting forces on the weakened mandible and improves access, yet it is insufficient for a complete bony reconstruction. After trimming of the coronoid process it nicely fits over the compacta defect allowing faster bony restoration. Because the condylar head and neck do not offer sufficient bone for placement of osteosynthesis, material osteosynthesis should be avoided. An absorbable plate (ARAUJO et al. 2001, ASHAMMAKHI et al. 2001) fixed to the lower portion of the ramus allows enough stability to avoid rotation of the graft. Ideal healing and bone formation was noticed through 6 months and 1 year controlling CT-scans (fig. 5 and 6).

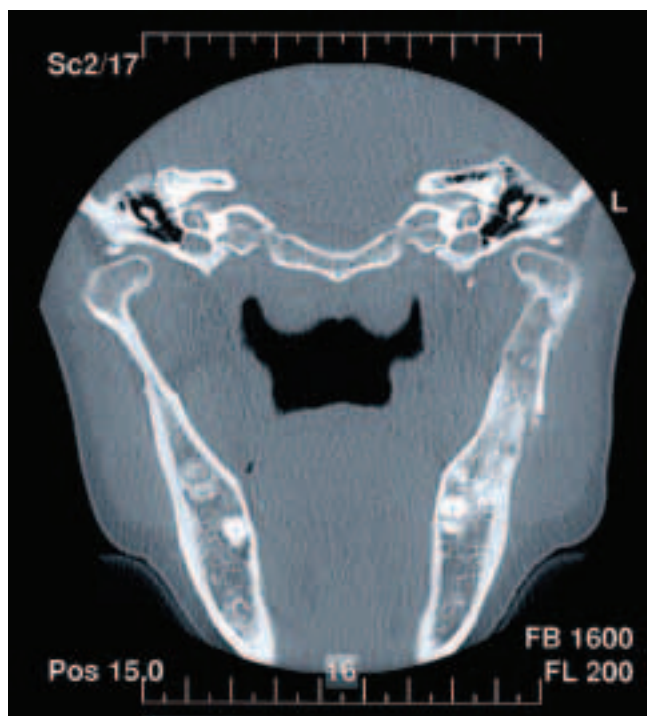

Fig. 5 Controlling CT-scan section after 6 months post operatively showing the coronoid cover

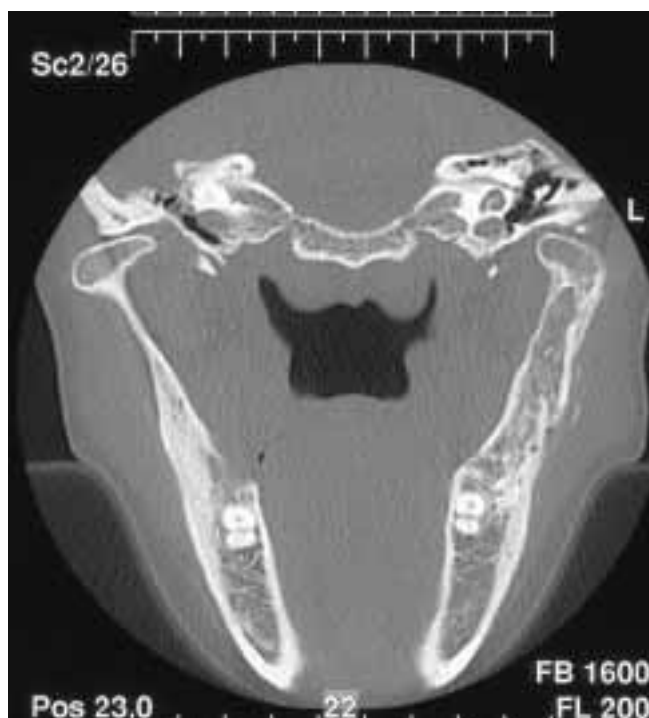

Fig. 6 One year controlling CT-scan section

Conclusion

Annual control visits with panoramic radiographs are appropriate in cases of symptom free, highly aberrated wisdom teeth with dentogenous cysts. If the indication for removal has been established, careful planning utilizing high resolution CT-scans must be performed. The intraoral approach shows lowest risk and should, therefore, be used as primary access. Excessive forces to the bony frame must be avoided by removing the tooth in fragments. Immobilization with rubber bands and resection of the coronoid process reduces biting forces.

References

- NODINE A M: Impacted and aberrant teeth-history, causes, and treatment. *Dent Items Interest* 68: 30, 1946
- BALENDRA W: Unerupted lower third molar in the region of the condyle. *British Dent J* 87: 229, 1949
- ZERNOV M W: Misplaced third molar in the region of the condyle erupting through the cheek. *British Dent J* 87: 295, 1949
- SZERLIP L, MORRISTOWN N J: Displaced third molar with dentigerous cyst – an unusual case. *J Oral Surgery* 36: 551–52, 1978
- LOCHER C M, CARLS F, PAJAROLA G F: Severe complications after surgical removal of wisdom teeth. *Fortschr Kiefer Gesichtschir.* 40: 123–8, 1995
- BURTON D J, SCHEFFER R B: Serratia infection in a patient with bilateral subcondylar impacted third molars and associated dentigerous cysts: report of case. *J Oral Surgery* 38: 135–38, 1980
- OIKARINEN V J, ALTONEN M: Impacted third molar in condyloid process : Report of a case. *Oral Surgery* 30: 7–10, 1970
- ARAUJO M M, WAITE P D, LEMON J E: Strength Analysis of Le Fort I Osteotomy Fixation: Titanium Versus Absorbable Plates. *J Oral Maxillofac Surg* 59: 1034–39, 2001
- ASHAMMAKHI N, PELTONIEMI H, WARIS E, SUURONEN R, SERLO W, KELLOMÄKI M, TÖRMÄLÄ P, WARIS T: Special Topic: Developments in Craniomaxillofacial Surgery: Use of Self-Reinforced Bioabsorbable Osteofixation Devices. *Plast Reconstr Surg* 108: 167–180, 2001