

Research · Science Forschung · Wissenschaft Recherche · Science

Publisher

Herausgeber
Editeur

Schweizerische Zahnärzte-
Gesellschaft SSO
Société Suisse
d'Odonto-Stomatologie
CH-3000 Bern 7

Editor-in-chief

Chefredaktor
Rédacteur en chef

Prof. Adrian Lussi
Klinik für Zahnerhaltung,
Präventiv- und
Kinderzahnmedizin
Freiburgstrasse 7
3010 Bern

Editors

Redaktoren
Rédacteurs

Andreas Filippi, Basel
Susanne Scherrer, Genève
Patrick R. Schmidlin, Zürich

Assistant Editor

Redaktions-Assistent
Rédacteur assistant

Simon Flury, Bern
Klaus Neuhaus, Bern
Brigitte Zimmerli, Bern

Jede im Teil «Forschung und Wissenschaft» der SMfZ eingereichte Arbeit wird von zwei bis drei zahnärztlichen Fachpersonen begutachtet. Diese genaue Begutachtung macht es möglich, dass die Publikationen einen hohen wissenschaftlichen Standard aufweisen.

Ich bedanke mich bei den unten aufgeführten Kolleginnen und Kollegen für ihre wertvolle Mitarbeit, die sie in den vergangenen zwei Jahren geleistet haben.

Adrian Lussi

M. Altenburger, Freiburg
N. Arweiler, Marburg
T. Attin, Zürich
M. M. Bornstein, Bern
D. Buser, Bern
V. Chappuis, Bern
K. Dula, Bern
N. Enkling, Bern
A. Filippi, Basel
T. Flemming, Seattle
S. Flury, Bern
W. Gnoinski, Zürich

K. W. Grätz, Zürich
C. Hämmerle, Zürich
S. Hänni, Bern
E. Hellwig, Freiburg
C. Katsaros, Bern
N. Kellerhoff, Bern
J. T. Lambrecht, Basel
K. Lädach, Bern
H. T. Lübbers, Zürich
R. Männchen, Winterthur
C. Marinello, Basel
G. Menghini, Zürich

R. Mericske-Stern, Bern
A. Mombelli, Genève
F. Müller, Genève
K. Neuhaus, Bern
I. Nitschke, Zürich
C. Ramseier, Bern
S. Ruf, Giessen
G. Salvi, Bern
M. Schätzle, Luzern
S. Scherrer, Genève
P. R. Schmidlin, Zürich
A. Sculean, Bern

R. Seemann, Bern
P. Sequeira, Bern
U. Thüer, Meikirch
H. van Waes, Zürich
T. von Arx, Bern
C. Walter, Basel
T. Waltimo, Basel
R. Weiger, Basel
M. Zehnder, Zürich
B. Zimmerli, Bern
N. U. Zitzmann, Basel

SILVIO SCHÜTZ
ISABELLE BECK
SEBASTIAN KÜHL
ANDREAS FILIPPI

Department of Oral Surgery,
Oral Radiology and Oral Medicine
School of Dental Medicine
University of Basel
Hebelstrasse 3
CH-4056 Basel

Correspondence

Dr. Silvio Schütz
Department of Oral Surgery, Oral
Radiology and Oral Medicine
School of Dental Medicine
University of Basel
Hebelstrasse 3
CH-4056 Basel
Tel. +41 61 267 26 10
Fax +41 61 267 26 07
E-mail: silvio.schuetz@unibas.ch
Schweiz Monatsschr Zahnmed 123:
303–308 (2013)
Accepted for publication:
19 September 2012

Results after wisdom tooth transplantation

A retrospective study

Keywords: tooth transplantation, wisdom tooth, agenesis

SUMMARY Wisdom tooth transplants offer youth the possibility of biologically fixed tooth replacement in cases of premolar agenesis or premature loss of a molar. In the present study, 57 transplants of third molars were reviewed and evaluated retrospectively on preoperative findings (root growth stages, extraction sites, indication for transplantation), on postoperative clinical findings (local gingivitis, periodontal probing values, tooth mobility, percussion sound and percussion pain) and on radiological findings (tertiary build-up of dentin, osseous periradicular conditions, progress of root growth). Only the transplants which healed with a vital pulp and in a periodontally healthy state were considered successful.

Upper and lower wisdom teeth having 50% to 75% root growth progression were transplanted. The postoperative follow-up observation period averaged 26.4 months. The success of a wisdom tooth transplantation was not influenced by the root growth stage ($p=1$), the extraction location of wisdom teeth ($p=0.45$), or the feasibility for a transplantation ($p=0.56$). Three teeth showed pulpal necrosis with apical periodontitis and were counted as failures. The success rate was rather high with 54 out of 57 transplants (94.7%), therefore wisdom tooth transplantations, with careful selection of a suitable graft and its gentle removal, can be described as a good predictable treatment.

Introduction

Typical indications for wisdom tooth transplants are agenesis of premolars or the replacement of non-repairable first or second molars (FILIPPI 2009). Suitable transplant root growth should have a development of 50% to 75%, as on the one hand healing of periodontal tissue needs a certain root length, and on the other hand, root development that is too advanced deters revascularization of the pulp (HENRICHVARK & NEUKAM 1987, ANDREASEN 1992, KALLU ET AL. 2005). In germinating teeth with less root development, the risk of reduced root formation increases (SLAGSVOLD & BJERCKE 1978, ESKICI 2003). In order to avoid extended cell damage to the root surface, the graft should be removed gently. Impacted and improperly aligned wisdom teeth are therefore less suitable for transplantations (FILIPPI 2009). After graft removal, the transplant should be kept in a nutrient solution (Dentosafe®, Tooth Box, Medice, Iserlohn, Germany; Curasafe®, Curaden, Kriens, Switzerland; SOS Tooth

Box®, Miradent, Duisburg, Germany) for at least 15 minutes to preserve the vitality of periodontal cells (POHL ET AL. 2005). To increase the likelihood of pulp revascularization, the grafts can be immersed in a tetracycline solution (1 mg of tetracycline powder dissolved in 20 ml of sterile isotonic saline) or into a tetracycline/dexamethasone solution (NoResorb®, 1 mg of tetracycline/1 mg dexamethasone, Medcem Weinfelden, Switzerland, dissolved in the tooth rescue box) for 5 minutes (YANPISET & TROPE 2000). For transplant fixation, the use of a titanium trauma splint has been proven useful (TTS Medartis, Basel, Switzerland) (VON ARX ET AL. 2001, FILIPPI ET AL. 2002).

Previous studies have shown success rates of 79% to 100% (ANDREASEN ET AL. 1970, NETHANDER ET AL. 1988, LUNDBERG & ISAKSSON 1996, BAUSS ET AL. 2002, SCHULTZE-MOSGAU & NEUKAM 2002, REICH 2008). Because the success criteria were defined differently, and the duration of the observation periods varied in each of the individual studies, the results can only be compared with each other in a limited fashion. Transplantations

with a newly created alveolus had similar successful healing rates as those of simultaneous transplants in fresh alveoli (CONKLIN 1974, BAUSS ET AL. 2004).

Periodontal healing begins with the restoration of the gingival attachment, which is completed within a week. The periodontal ligament fibers are re-formed after 2 to 4 weeks (FILIPPI 2009). After a transplantation, the pulp first necrotizes. With a wide open apical foramen, revascularization of the pulp starts already after 3 to 4 days. Revascularization is normally completed after 4 to 5 weeks. The revitalized pulp leads to a narrowing or obliteration of the pulpal canal, the vertical root growth proceeds by at least 1 to 2.5 mm (ANDREASEN 1992).

The aim of this study was to determine the success rate of wisdom tooth transplants. Possible correlations were studied between the success rate of transplants and the root growth stages of wisdom teeth, the extraction point of the grafts and the feasibility for transplantation.

Materials and methods

In this retrospective study, 57 wisdom tooth transplants from 46 patients (25 men, 21 women) were tested (of the 63 beginning cases, 6 were excluded due to lack of data). In 11 cases, 2 teeth per patient were transplanted. The average age of the patients at the time of transplantation was 17.2 years (14–21 years, SD: 1.8). The investigated transplantations took place between the end of 2004 and the beginning of 2011.

The transplants were examined preoperatively using panoramic radiographs to determine their root growth stages, classified according to Demirjian (DEMIRJIAN ET AL. 1973) and then evaluated. The following data was recorded: the extraction sites of the transplants, the location of the transplantation, the feasibility for transplantation as well as the patient's age.

All transplants were performed by one surgeon (Fig. 1–5). First, the graft was carefully removed to avoid tissue damage. With erupted wisdom teeth, the cervical periodontium was distinctly separated with an incision in the sulcus (TSUKIBOSHI 2002). Unerupted wisdom teeth were removed preserving the

dental follicle. In both cases, tilting movements were applied so that compression of the periodontal ligament was avoided. If, in the recipient area, a non-repairable primary or secondary molar was still in situ, it was removed without a flap, but after a sharp division of the circular fibers and usually after separation of the roots.

All grafts were placed into a tooth rescue box containing organ transplant medium for at least 15 minutes. Grafts having a small diameter of the apical foramen (1.5 mm–2 mm) were also immersed for 5 minutes into a tetracycline solution (1 mg of tetracycline powder dissolved in 20 ml of sterile isotonic saline) or into a tetracycline/dexamethasone solution (NoResorb®, Tetracycline 1 mg/1 mg dexamethasone, Medcem Weinfelden, Switzerland; since its launch in 2010, this product was always used, dissolved in the tooth rescue box, in which 23 out of the 57 transplants were placed). If periodontal ligament damage was expected as a result of a difficult graft removal, the root surface was additionally treated with Emdogain® (Straumann, Basel, Switzerland), (4 out of 57 grafts). The transplant bed was adapted to the transplant with burs under appropriate cooling with sterile isotonic saline. After transplantation, all wisdom teeth were positioned in occlusal contact with the antagonists. When fixed orthodontic appliances were present (7 of 57 cases), the grafts were secured to these appliances. Otherwise, splinting was done to the adjacent teeth with a titanium trauma splint (49 of 57). With perfect primary stability a criss-cross suture was applied (1 case). The average duration of fixation was 34 days (14–66 days, SD: 13.9). The sole postoperative medications were analgesics; antibiotics were never necessary.

One month postoperatively, the patients were assessed for local gingivitis, loosening of the splint and occlusal interferences (pain by tapping, premature contacts). In each case, the presence of findings were recorded but not described with special indices.

As a result, examinations were made 6 and 12 months postoperatively and then each year thereafter. Evaluation of the present study included the findings of each previous patient

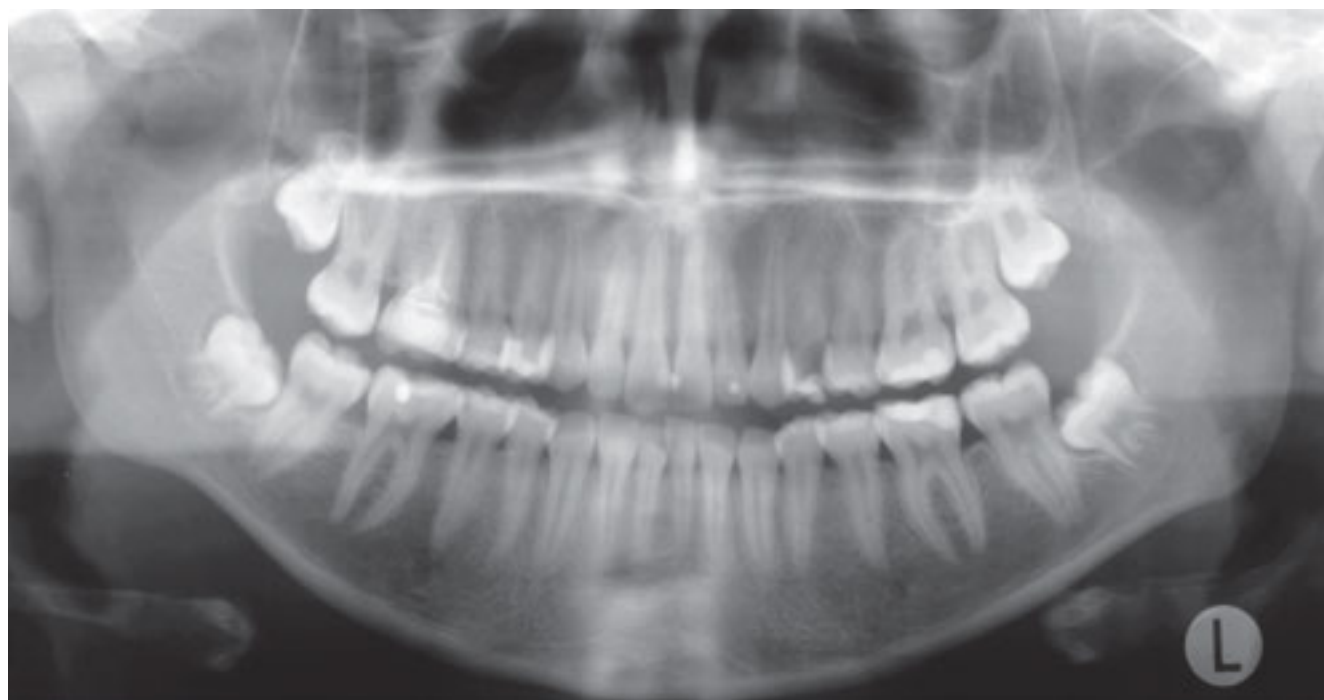


Fig. 1 Preoperative panoramic radiograph of a 15 year old patient with insufficient root canal treatment and apical periodontitis tooth 16

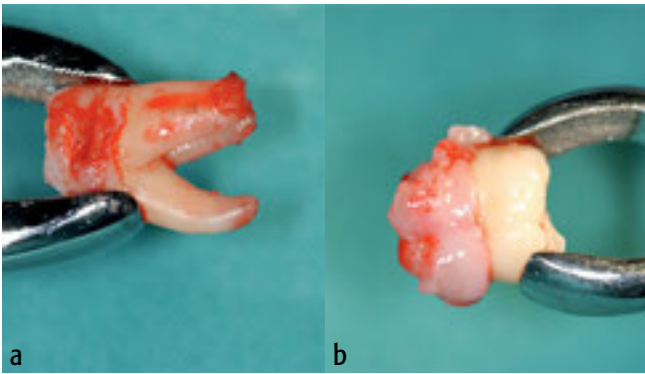


Fig. 2 Removed teeth 16 (2a), and 18 (2b)

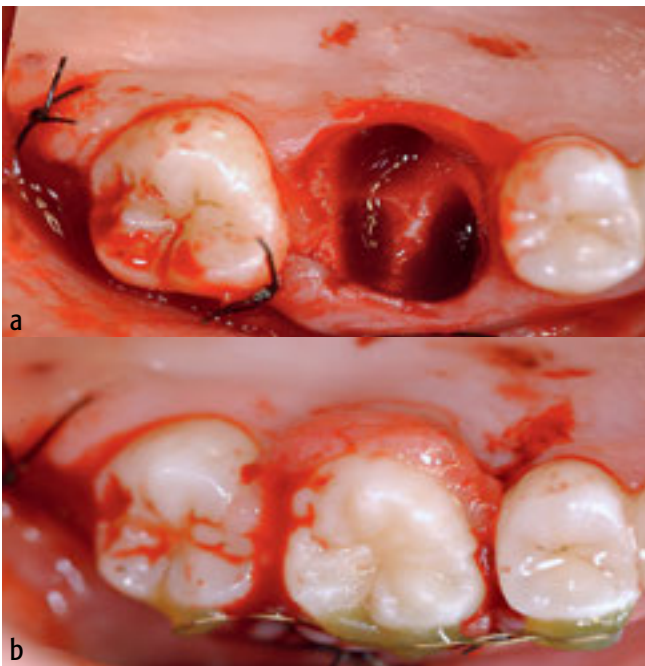


Fig. 3 Clinical situation after removal of teeth 18 and 16 (3a) and transplantation 18 at point 16, fixed with a titanium trauma splint (3b)

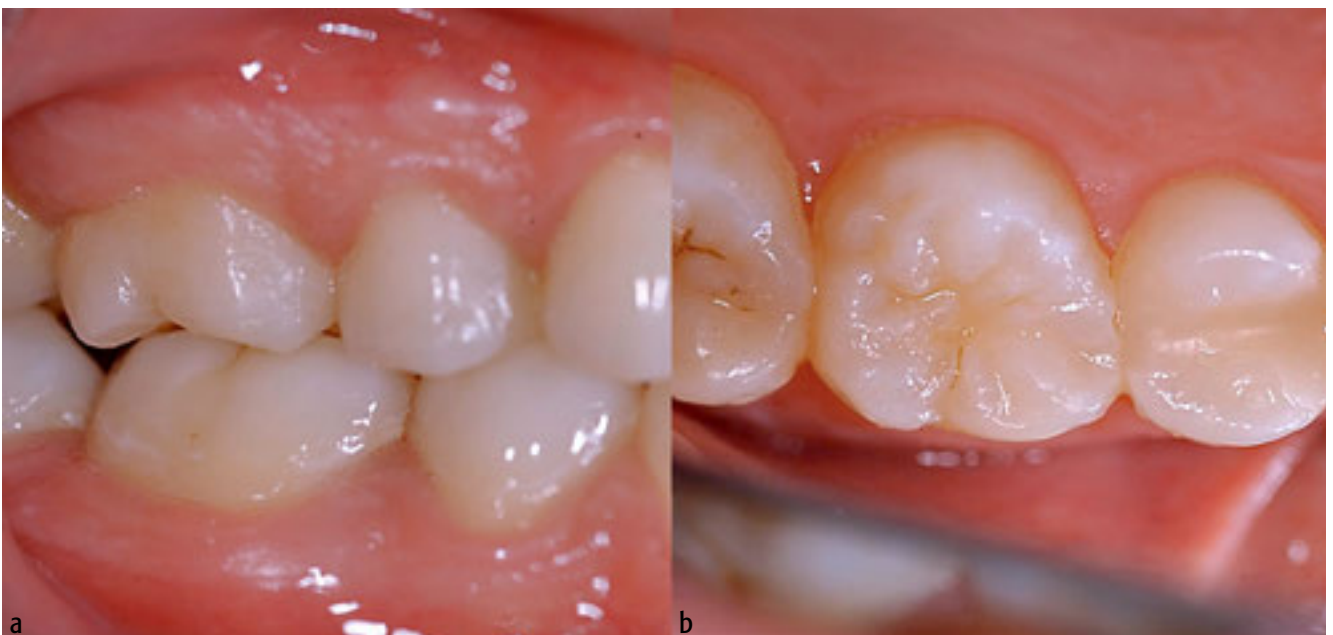

Fig. 5 Clinical situation one year postoperatively (side view 5a, 5b occlusal)

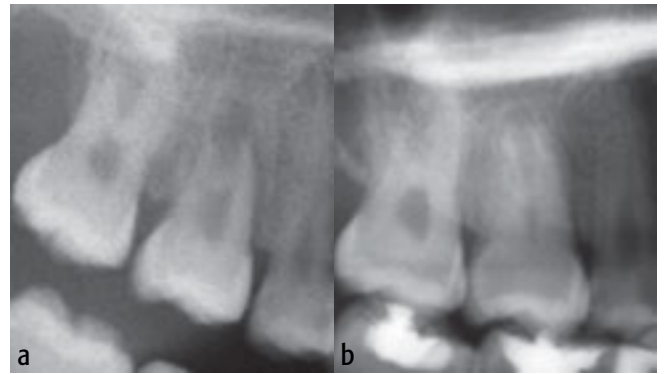


Fig. 4 Postoperative radiograph (4a) and radiograph after one year (4b), with a narrowed pulp chamber and root growth of advanced tooth 18 to point 16

examination. These examinations took place after an average of 26.4 months (8–64 months, SD: 16.5). Clinically, local gingivitis (yes or no), periodontal probing depth values (in millimeters), tooth mobility (according to LINDHE & NYMAN 1977), percussive sensitivity (yes or no) and perception of percussion sound (normal/bright/dull) were recorded. The pulp was assessed radiologically (panoramic radiographs). A distinction was made between obliteration, narrowing or no change in the pulp chamber or root canal, and between a progression of root growth and its absence. All teeth that showed either an obliterated/narrowed pulp or progress in root growth were considered vital. On the other hand, the continuous traceability of the periodontal ligament was examined. Distinction was made between a normal or widened periodontium and a periapical lesion.

A successful transplant consisted only of teeth with the following criteria: a periodontally healthy situation (consistent traceable periodontal ligament visible on radiographs, normal percussion sound, healthy gingiva, no pathologically increased probing depths, no non-physiological tooth mobility) and a vital pulp (obliterated/narrowed pulp and/or root growth progress). Probing depths greater than 3 mm were considered pathologic and tooth mobility with grades II and III were considered non-physiologic (LANG ET AL. 2003, SAVAGE ET AL. 2009).

Statistical analysis of the results was performed using the program R (version 2.12.2, 'The R Foundation for Statistical Computing, Vienna, Austria'). The success of the transplants was compared with growth of wisdom tooth roots, removal location of the grafts (upper or lower jaw) and transplant feasibility. As a standard of significance, a probability error of 0.05 was chosen. Fisher's exact test was used for the calculation of the p-values.

Results

Of the 57 transplanted wisdom teeth, about half (26 teeth) were taken during root growth stage F (progress of root growth 75%, apical foramen wide open; according to DEMIRJIAN ET AL 1973). 19 of the 57 grafts already showed more advanced root growth (G: vertical root growth almost complete, apical foramen still open), 12 were in an earlier stage (E: progress of root growth 50%).

In 34 cases, the indication for transplantation was a non-repairable first or second molar. Reasons for the loss of a first or second molar were caries, inadequate root canal treatments, apical periodontitis, as well as fractures of the teeth. In 23 cases, the transplants were due to non-existence of a second premolar. At the time of transplantation, the patients with non-repairable molars were on average 17 years old (14–19.5 years, SD=1.7), those with a premolar aplasia a year older (average 17.9 years, 15–21, SD=1.9). Most wisdom teeth were removed in the maxillary arch and then used to replace the first molar or the second premolar (Table I).

During check-ups one month postoperatively, three-quarters of the patients (42) showed neither local gingivitis nor premature occlusal contacts, percussive pain or detachment of the splint (Table II). Twelve teeth showed only one of the above findings and two teeth had percussive pain together with local gingivitis. One tooth had a periodontal infection which did not heal and was lost.

The most recent postoperative check-ups that were included in the study showed 52 patients with healthy clinical conditions (Table II). A second tooth was lost after a year due to pulpal necrosis and apical periodontitis after an unsuccessful root canal treatment. The clinical findings of this tooth showed gingivitis and pathologically increased probing depths (circular 5–6 mm). Another tooth with a necrotic pulp had the same findings. These two teeth, together with the above-mentioned tooth, had to be removed during the healing phase and were considered failures.

Two more teeth showed isolated clinical findings: one tooth had locally increased probing measurements in one place (4 mm), and another tooth had mobility grade II. Since both teeth were in healthy periodontal condition, had no local gingivitis and had pulpal vitality, they were not regarded as failures.

On the basis of radiographic findings at the last examination, the pulp was seen as vital in 54 teeth (Table III). Of the five teeth with non-obiterated pulps only two showed no progress in root growth. These additionally showed apical lesions, which is why the diagnosis of pulp necrosis was made. These were the same two transplants, based on clinical findings, which were already counted as failures.

The periodontal ligament on all teeth was consistently traceable. Broadening of the periodontal ligament could only be seen in teeth with apical periodontitis.

A statistically significant correlation between the success of transplantation and root growth stages E–G (p=1), the donor

	Maxillary arch	Mandibular arch	Total
Extraction			
Third molar	27 (region of 18) and 20 (region of 28)	6 (region of 38) and 4 (region of 48)	57
Location of transplant			
Second molar	1	2	3
First molar	19	12	31
Second premolar	6	17	23

	1 month post-operative	Last post-operative examination
No findings	42	52
Gingivitis	7	2
Loosened splint	8	n. a.
Premature occlusal contact	0	n. a.
Non-occlusion	0	0
Percussion pain	2	0
High/dull percussion sound	n. a.	0
Pathologically increased probing measurements	n. a.	3
Non-physiologic tooth mobility	n. a.	1
Loss	1	2

n.a. = not examined

Pulp			Root growth	
Obliterated	Narrowed	Not obliterated	Progress	No progress
12	39	5	51	5

site of the graft (upper or lower jaw) (p=0.45) and the indication for transplantation (p=0.56) could not be ascertained.

Discussion

Of the 57 transplanted wisdom teeth, 54 were considered successful (94.7%). One failure occurred during the healing phase, as an infection of the periodontium arose, and two weeks after surgery, the tooth had to be removed again (transplant tooth 28 with root growth stage E, region 35, with agenesis). The root length of the wisdom tooth was at the lower limit of the recommended length for root grafts, which could be one reason for the failure (HENRICHVARK & NEUKAM 1987, ANDREASEN 1992,

KALLU ET AL. 2005). Two months after the first transplantation, tooth 18 (also in root growth stage E) was transplanted to region 35. After one year, this tooth was successfully in situ with a healthy periodontium and a vital pulp.

After one year, the second tooth presented with local gingivitis, increased probing depths and pulp necrosis. This tooth 28 (root growth stage F) was grafted into region 45 because of agenesis. Although a root canal treatment was carried out, an apical periodontitis emerged again, so that the tooth had to be removed at the age of 21. An implant was then placed to fill the gap.

The third tooth had to be declared as failure one year post-operatively as there were increased probing depths, pulp necrosis and apical periodontitis (transplant tooth 48 with root growth stage G to region 36 with a non-repairable molar). Despite repeated recalls, the patient did not show up for the required root canal treatment and it is unclear to date what has happened to this tooth.

Vitality testing with CO₂ in follow-up exams was not carried out since the results of such tests of obliterated or narrowed pulps are not conclusive. Formation of tertiary dentin, which progresses from the narrowing to the obliteration of the pulpal cavity, requires living cells. These can only be fed via vital pulp tissue which must grow into the pulp cavity after transplantation. Therefore, radiological findings of a visible pulp reaction must be considered vital pulp tissue, even if these teeth react negatively to the sensibility test with CO₂ (FILIPPI 2009).

Transplantations are basically only indicated when the width and height of the existing bone volume in the area of the recipient bed exceeds the width and length of the roots of the grafts. The transplant bed also needs to be free from acute infection at the time of transplantation. Due to root anatomy, mainly upper wisdom teeth are used as transplants, which is confirmed in the present study with 47 upper third molars and with 10 lower ones. It is important that the teeth are removed without extensive osteotomies, without severe dislocation movements and are positioned in the transplant bed without using pressure. Damage caused by the crushing of periodontal cells should be avoided. If damage to the periodontal ligament cells is suspected after elaborate removal of the graft, it can be treated with Emdogain® (Straumann, Basel, Switzerland). Emdogain® stimulates proliferation of periodontal cells thus repairing the damaged areas of the periodontal ligament (GESTRELIUS ET AL. 1997, HAMMARSTRÖM 1997). In the present study, Emdogain® was only used in 4 cases. The successful effect of Emdogain® is controversial. Avulsed and later re-transplanted teeth showed no decreased ankylosis or root resorption compared with teeth which were not treated with Emdogain® (WERDER ET AL. 2011).

After the graft is removed it should be placed in a nutrient medium for 15 minutes (Dentosafe®, Curasafe® or SOS® tooth box) (POHL ET AL. 2005). Possibly damaged periodontal cells on the root surface can better regenerate and resulting toxins of damaged tissue will also be better flushed out in the nutrient medium than when the graft is surrounded with coagulum of the periodontium (KRASNER & RANKOW 1995).

Next, it is recommended that the graft be immersed for 5 minutes in a tetracycline solution or a tetracycline/dexamethasone solution (YANPISET & TROPE 2000). The antibiotic enhances revascularization of the pulp by microbial reduction. The glucocorticoid acts topically on the periodontal ligament cells and prevents further resorption and ankylosis. In this study, 23 of 57 teeth were immersed in the tetracycline solution or in the tetracycline/dexamethasone solution. Because of the small number of failures, there is not a conclusive recommendation on the need for this medication (one lost graft was treated with the solution and two grafts were treated without the solution)

The statistical analysis of the relationship between the success of the transplants and the root growth stages of the molars, the origin of the grafts and the transplant indications showed no significance. The reasons are likely to be the high success rate of third molar transplantations (94.7%), the small number of samples and the retrospective study design.

The present study demonstrated, together with rigorously chosen assessment criteria, a high success rate of wisdom teeth transplantations. For younger people, this offers the possibility of fixed biological substitution of a tooth in cases of premolar agenesis or a premature loss of a molar. Implant restorations in this age group are still not the alternative.

Résumé

La transplantation des dents de sagesse permet aux jeunes adolescents d'avoir une dent de remplacement fixe et biologique dans le cas d'une agénésie de prémolaire ou d'une perte prématurée d'une molaire. Dans la présente étude, 57 transplantations de dents de sagesse ont été examinées rétrospectivement quant aux données préopératoires (les stades de développement des racines, les localisations d'extraction, l'indication de la transplantation), aux données postopératoires cliniques (gingivite locale, les valeurs de sondage parodontales, la mobilité dentaire, la percussion et la douleur de pression) et des données radiographiques (la formation de dentine tertiaire, les conditions osseuses périradiculaires, le progrès de développement des racines). Seules les transplantations présentant un parodont sain et une pulpe vitale ont été considérées comme étant un succès.

Des dents de sagesse des maxillaires supérieures et inférieures avec un stade de développement des racines de 50% à 75% ont été transplantées. Le suivi postopératoire a été de 26,4 mois en moyenne. Ni le stade de développement des racines, ($p=1$), ni les lieux d'extraction des dents de sagesse ($p=0,45$), ni l'indication de la transplantation ($p=0,56$) n'ont eu d'influences sur le succès de la transplantation des dents. Trois dents ont développé une nécrose pulpaire avec parodontite apicale et ont été considérées comme des échecs. Le taux de réussite fut élevé (54 sur 57 transplantations, 94,7%). C'est pourquoi la transplantation d'une dent de sagesse peut être considérée comme étant un traitement très prévisible, lors d'une sélection rigoureuse d'un transplant approprié et d'une explantation sans traumatisme.

References

- ANDREASEN J O: Atlas of replantation and transplantation of teeth. Mediglobe SA, Fribourg (1992)
- ANDREASEN J O, HJÖRTING-HANSEN E, JOLST O: A clinical and radiographic study of 76 autotransplanted third molars. *Scand J Dent Res* 78: 512–523 (1970)
- BAUSS O, ENGELKE W, FENSKE C, SCHILKE R, SCHWESTKA-POLLY R: Autotransplantation of immature third molars into edentulous and atrophied jaw sections. *Int J Oral Maxillofac Surg* 33: 558–563 (2004)
- BAUSS O, SADAT-KHONSARI R, ENGELKE W, KAHL-NIEKE B: Results of transplanting developing third molars as part of orthodontic space management. Part 1: Clinical and radiographic results. *J Orofac Orthop* 63: 483–492 (2002)
- CONKLIN W W: Transplantation of third molar into edentulous site. *Oral Surg Oral Med Oral Pathol* 38: 193–197 (1974)
- DEMIRJIAN A, GOLDSTEIN H, TANNER J M: A new system of dental age assessment. *Hum Biol* 45: 221–227 (1973)
- ESKICI A: Reimplantation und Transplantation von Zähnen. *Praxis der Zahnheilkunde*. Urban & Fischer, München (2003)
- FILIPPI A: Zahntransplantation. *Biologischer Zahnersatz für Kinder, Jugendliche und manche Erwachsene*. 1. Aufl., Quintessenz, Berlin (2009)
- FILIPPI A, VON ARX T, LUSSI A: Comfort and discomfort of dental trauma splints – a comparison of a new device (TTS) with three commonly used splinting techniques. *Dent Traumatol* 18: 275–280 (2002)
- GESTRELIUS S, ANDERSSON C, LIDSTRÖM D, HAMMARSTRÖM L, SOMERMAN M: In vitro studies on periodontal ligament cells and enamel matrix derivative. *J Clin Periodontol* 24: 685–692 (1997)
- HAMMARSTRÖM L: Enamel matrix, cementum development and regeneration. *J Clin Periodontol* 24: 658–668 (1997)
- HENRICHVARK C, NEUKAM F W: Indikation und Ergebnisse der autogenen Zahntransplantation. *Dtsch Zahnärztl Z* 42: 194–197 (1987)
- KALLU R, VINCKIER F, POLITIS C, MWALLI S, WILLEMS G: Tooth transplantations: a descriptive retrospective study. *Int J Oral Maxillofac Surg* 34: 745–755 (2005)
- KRASNER P, RANKOW H J: New philosophy for the treatment of avulsed teeth. *Oral Surg Oral Med Oral Pathol Oral Radiol Endod* 79: 616–623 (1995)
- LANG B, POHL Y, FILIPPI A: Transplantation von Zähnen. *Schweiz Monatsschr Zahnmed* 113: 1178–1199 (2003)
- LINDHE J, NYMAN S: The role of occlusion in periodontal disease and the biological rationale for splinting in treatment of periodontitis. *Oral Sci Rev* 10: 11–43 (1977)
- LUNDBERG T, ISAKSSON S: A clinical follow-up study of 278 autotransplanted teeth. *Br J Oral Maxillofac Surg* 34: 181–185 (1996)
- NETHANDER G, ANDERSSON J E, HIRSCH J M: Autogenous free tooth transplantation in man by a 2-stage operation technique. A longitudinal intra-individual radiographic assessment. *Int J Oral Maxillofac Surg* 17: 330–336 (1988)
- POHL Y, FILIPPI A, KIRSCHNER H: Results after replantation of avulsed permanent teeth. II. Periodontal healing and the role of physiologic storage and antiresorptive-regenerative therapy. *Dent Traumatol* 21: 93–101 (2005)
- REICH P: Autogenous transplantation of maxillary and mandibular molars. *J Oral Maxillofac Surg* 66: 2314–2317 (2008)
- SAVAGE A, EATON K A, MOLES D R, NEEDLEMAN I: A systematic review of definitions of periodontitis and methods that have been used to identify this disease. *J Clin Periodontol* 36: 458–467 (2009)
- SCHULTZE-MOSGAU S, NEUKAM F W: Intentionelle Replantation, therapeutische Zahnluxation, Zahntransplantation. In: Reichart P A, Hausamen J E, Becker J, Neukam F W, Schliephake H, Schmelzeisen R (Hrsg.): *Zahnärztliche Chirurgie*. Quintessenz, Berlin, pp 263–290 (2002)
- SLAGSVOLD O, BJERCKE B: Indications for autotransplantation in cases of missing premolars. *Am J Orthod* 74: 241–257 (1978)
- TSUKIBOSHI M: Autotransplantation of teeth: requirements for predictable success. *Dent Traumatol* 18: 159–180 (2002)
- VON ARX T, FILIPPI A, LUSSI A: Comparison of a new dental trauma splint device (TTS) with three commonly used splinting techniques. *Dent Traumatol* 17: 266–274 (2001)
- WERDER P, VON ARX T, CHAPPUIS V: Treatment outcome of 42 replanted permanent incisors with a median follow-up of 2.8 years. *Schweiz Monatsschr Zahnmed* 121: 312–320 (2011)
- YANPISSET K, TROPE M: Pulp revascularization of replanted immature dog teeth after different treatment methods. *Endod Dent Traumatol* 16: 211–217 (2000)